



Myofascial Pain and Treatment

Physical therapy treatment of a pediatric patient with symptoms consistent with a spinal cord injury without radiographic abnormality: A retrospective case report

Raymond Butts^{a, b, *}, Owen Legaspi^c, Adriana Nocera-Mekel^c, James Dunning^{b, d}^a Research Physical Therapy Specialists, Columbia, SC, USA^b American Academy of Manipulative Therapy, Montgomery, AL, USA^c A Plus Physical Therapy, Livingston, NJ, USA^d Montgomery Osteopractic Physiotherapy and Acupuncture Clinic, Montgomery, AL, USA

ARTICLE INFO

Article history:

Received 4 May 2020

Received in revised form

22 December 2020

Accepted 13 January 2021

Keywords:

Manipulation

Osteopathic

Pediatric

Spinal cord injury

ABSTRACT

Background: A spinal cord injury without radiographic abnormality (SCIWORA) is a relatively uncommon event that occurs in children following cervical trauma primarily due to sports-related injuries or physical abuse.

Case description: This case report describes an 11-year-old wrestler that developed signs and symptoms consistent with a SCIWORA following neck trauma during competition. Despite all diagnostic tests being inconclusive, the patient demonstrated increased cervical, thoracic, and lumbar paraspinal tone along with pain, loss of sensation, loss of mobility, and weakness of the lower extremities. As a result, the patient was confined to a wheelchair and required maximum assistance to transfer and ambulate with a walker. The patient was referred to physical therapy nine days after the traumatic event, where he received interferential current with moist heat, myofascial release of paraspinal muscles, functional exercise, gait training, and spinal manipulative therapy targeting the cervical, thoracic, and lumbar vertebrae.

Outcome: After 13 physical therapy treatments over 5-weeks, the patient was able to ambulate independently and perform all activities of daily living without pain or functional limitation. The following case report outlines this patient's successful journey toward recovery.

Conclusion: This case report suggests that spinal manipulative therapy may be a safe and effective intervention when used within a multi-modal treatment strategy for patients with signs and symptoms consistent with SCIWORA. Moreover, spinal manipulative therapy may be considered a beneficial treatment in some pediatric patients. However, this report describes a single patient, and further research is required on the use of spinal manipulation in this patient population.

© 2021 Elsevier Ltd. All rights reserved.

1. Background

A spinal cord injury without radiographic abnormalities (SCIWORA) is a clinically significant post-traumatic myelopathy without radiographic and/or computer tomography (CT) abnormalities (Bonfanti et al., 2018). Moreover, only two-thirds of patients have pathological findings per magnetic resonance imaging (MRI) (Bonfanti et al., 2018; Pang and Pollack, 1989). First described in 1974 (Burke, 1974) and identified in pediatric patients in 1982

(Pang and Wilberger, 1982), SCIWORA occurs mostly in children due to hypermobility and ligamentous laxity of the spine, which allows musculoskeletal structures to move beyond their physiologic limits, resulting in cord trauma without vertebral column disruption (Heydemann et al., 2020; Kriss and Kriss, 1996). Patients diagnosed with SCIWORA can present with a variety of neurological deficits including paresthesia, changes in tendon reflexes, para/hemiparesis/plegia, incontinence, and positive cord signs along with pain, sensitivity, abrasions, and ecchymosis in the vicinity of the spinal column (Atesok et al., 2018; Schellenberg et al., 2011). Symptoms can begin immediately at the time of injury, or they can occur days later due to second-hit phenomenon, inflammation, and hematoma formation around the spinal cord (Atesok et al., 2018;

* Corresponding author. 1114 lake Bluff Circle, Louisville, KY 40245, USA.

E-mail address: raymond.butts@spinalmanipulation.org (R. Butts).

Szwedowski and Walecki, 2014). While the prevalence of SCIWORA ranges from 6 to 19% in children less than 8 years old and 9–14% in adults (Szwedowski and Walecki, 2014), a diagnosis of SCIWORA in adults continues to be a topic of debate throughout the literature (Bonfanti et al., 2018). Patients with SCIWORA are initially given corticosteroids and immobilization so as to promote healing and spinal stability and then sent for rehabilitation (Alshorman et al., 2020). However, outcomes are variable (Alshorman et al., 2020).

Spinal manipulative therapy (SMT) is an accurately localized, single, quick, and decisive moment of small amplitude, following careful positioning of the patient (Grieve, 1981). Although not energetic, the movement is designed to be faster than the patient's reaction time (Grieve, 1981) and create audible cavitations (Dunning et al., 2012, 2016; Reggars, 1996), leading to mechanical (Oliveira-Campelo et al., 2010), biochemical (Plaza-Manzano et al., 2014), neurophysiologic (Haavik and Murphy, 2012), and hypoalgesic changes (Savva et al., 2014). A number of studies have found spinal manipulation to be a useful treatment in the cervical (Dunning et al., 2012, 2016; Hurwitz et al., 2009; Leininger et al., 2014; Michaleff et al., 2012), thoracic (Dunning et al., 2012; Vindigni et al., 2019; Young et al., 2019), and lumbar spine (Bronfort et al., 2004; Team, 2004). However, the safety of SMT has been questioned, particularly in the cervical spine, secondary to neurovascular complications (Wand et al., 2012). Nevertheless, studies that have measured changes in mechanical forces (Austin et al., 2010; Symons et al., 2002; Wuest et al., 2010), blood flow (Erhardt et al., 2015; Quesnele et al., 2014; Thomas et al., 2013), and segmental positioning (Buzzatti et al., 2015) during cervical manipulation have uniformly reported minimal risk from the procedure. Murphy et al. found no causal relationship between cervical manipulation and vertebral artery dissections (Murphy, 2010). While the prevalence of serious adverse events varies widely and is unreliable, Rubenstein et al. concluded that the risk of serious adverse events following cervical and lumbar manipulation “should be considered negligible” (Rubenstein, 2008).

While many clinicians prefer not to use spinal manipulation on children and adolescents (Shafirir and Kaufman, 1992; Spigelblatt, 2002; Waimer, 2002), there is no sound research suggesting that it is harmful (Bolin, 2010). Nevertheless, patients must be carefully screened for appropriateness (Bolin, 2010; Garcia et al., 2016). When treating pediatric patients, special consideration must be placed on joint mechanics in relation to epiphyseal plates, which are influenced by the maturation of the ossification centers (Bolin, 2010). Anatomically, the facet joints in the pediatric cervical spine have not yet ossified, and the spinous processes have not fully developed (Dhal et al., 2006; Jarosz, 1999). Pediatric patients also have a disproportionately larger heads, weaker musculature, and ligamentous laxity, placing them at a higher risk for injury (Robinson et al., 2015). Despite unique anatomical and physiologic differences between the pediatric and adult C-spine, the risks are minimal in both populations (Dhal et al., 2006; Jarosz, 1999; Todd et al., 2015). Abdulla et al. reported safety incidents following manipulative procedures ranging from 0.23% to 9% (Abdulla et al., 2015).

A number of case studies and case series exist, supporting the use of SMT for pediatric patients. In Walston and Yake, 10–14 sessions of SMT and exercise were used to treat three adolescent patients with mechanical low back pain, resulting in a significant reduction in pain and disability (Walston and Yake, 2016). In three additional studies, SMT was successfully used to treat children with a bulging lumbar intervertebral disc (Zhao and Feng, 1997), “growing pains” associated with the lumbosacral spine (Alcantara and Davis, 2011), and neck pain with headaches (Roberts and Wolfe, 2009), respectively.

Spinal manipulation has also been found to facilitate recovery in

patients with neurologic symptoms (Dunning et al., 2016; Garcia et al., 2016; Tieppo Francio et al., 2017; Vining et al., 2018). Kachmar et al. reported improvements in gross motor function and reduced spasticity when SMT was administered to 29 patients with cerebral palsy ranging from 7 to 18 years old (Kachmar et al., 2016). In addition, SMT has been successfully incorporated into a multidisciplinary treatment approach for a partial cervical spinal cord injury following a traumatic motor vehicle accident (Vining et al., 2017). Despite multiple cervical spine fractures and a partial spinal cord injury, thrust manipulation to the thoracic and thoracolumbar region combined with upper extremity stretching, mechanical percussion, and soft tissue work to the cervico-occipital region led to decreased pain, improved function, and transfer to a long-term care facility (Vining et al., 2017).

The present case report involved an 11-year-old patient that suffered from signs and symptoms consistent with a SCIWORA following compression of the spine during a wrestling match. While auto accidents and falls are the most common mechanism of SCIs in infants and children (ages two to nine), respectively, incidents involving sports are the most common reason for SCIs in children 10–14 years old (Cirak et al., 2004). To our knowledge, this is the first study whereby SMT is used to treat a pediatric patient with symptoms consistent with a SCIWORA.

2. Case description

The case report involves an 11-year-old male patient that suffered a traumatic neck injury during a competitive wrestling match. The patient was attempting to maneuver his body so as to escape being pinned when he was lifted from behind by his opponent and dropped laterally onto his neck. His cervical spine was immediately stabilized, and the patient was transported to the nearest hospital for further evaluation. According to open-mouth views of the cervical spine and A-P and lateral views of the thoracic spine, there was no evidence of an upper cervical fracture. Computerized tomography (CT) and MRI images were negative for anatomical and structural defects. Magnetic resonance imaging (MRI) of the patient's brain, cervical spine, and thoracic spine were taken without contrast, but they were unremarkable. While MRI of the lumbar spine found moderate straightening of the lordosis, consistent with muscle spasms, there were no signs of herniated discs or central canal stenosis. Importantly, the spinal cord in the cervical, thoracic, and lumbar spine had a normal signal intensity and caliber. At the time of injury, the patient had no co-morbidities, and his past medical history was unremarkable. See Tables 1 and 2 for a timeline of the injury and the medical care that followed, respectively.

The patient's primary complaint was pain over the cervical, thoracic, and lumbar paraspinal muscles along with loss of strength and sensation in the lower extremities. As a result, he was unable to transition from sit-to-stand or ambulate without maximum assistance of two people. The patient's short-term goals were to improve function and decrease pain. Specifically, he wanted to be able to sit, stand, and ambulate independently without pain. His long-term goals were to return to previous level-of-function and participate in competitive sports.

3. Clinical impression

The patient is an 11 year-old, male wrestler that presented with signs and symptoms consistent with a SCIWORA, but without an official diagnosis. Given that all diagnostic tests were unremarkable and/or inconclusive, the patient's family requested physical therapy treatment. Please see Fig. 1 for radiographic images taken <2 hours after the traumatic injury. The patient presented to physical therapy (See Fig. 1) with a prescription to treat paraspinal pain and

Table 1
Timeline of patient's symptoms and corresponding medical treatment following traumatic injury.

| Timeline of Patient's Symptoms and Corresponding Medical Treatment Following Traumatic Injury | |
|---|--|
| Initial Injury (IR) | Patient suffers initial injury to cervical spine during wrestling match |
| IR + 1 Hour | Patient receives care at emergency department of local hospital, and initial images are taken |
| IR + 2 Hours | Patient is released from emergency department, as all diagnostic tests are negative |
| IR + 1 Day | Patient begins experiencing pain, guarding and spasms of cervical, thoracic and lumbar paraspinal muscles |
| IR + 3 Days | Patient is seen by orthopedic physicians and open-mouth C1–C2 images are taken |
| IR + 4 Days | Patient is admitted to hospital where he receives a CT and MRI scan after complaining of an inability to ambulate secondary to “heaviness” and numbness (bilaterally from mid thigh to toes) and loss of balance |
| IR + 7 Days | Patient released from hospital without a formal diagnosis |
| IR + 8 Days | Patient's mother requests referral from physical therapy |
| IR + 9 Days | Patient reports to first physical therapy treatment session |

Table 2
Manual therapy, modalities, and exercise provided during 13 physical therapy treatment sessions.

| PHYSICAL THERAPY (13 TOTAL TREATMENTS) | | | |
|--|--|---|---|
| TREATMENT | THERAPY | THERAPY DESCRIPTION | THERAPY OUTCOME |
| Manual Therapy | | | |
| 1–13 | Spinal Manipulation | 1. Cervical C2-7 rotatory HVLAT (cradle hold) - bilaterally 2. Cervicothoracic Junction (C7-T3) lateral flexion HVLAT in prone – bilaterally 3. Mid-thoracic (T2-T9) P-A extension HVLAT in prone 4. Lumbosacral junction (L5-S1) HVLAT in lateral recumbent with extension/rotation and sacral forearm pull - bilaterally | See below |
| | Myofascial Release | Myofascial release (instrument-assisted soft tissue mobilization) to paraspinal muscles of the cervical, thoracic, lumbar spine - bilaterally | |
| Modalities | | | |
| 1–13 | Moist Heat and Interferential Current | Moist heat and interferential current to cervical, thoracic and lumbar paraspinal muscles X15 Minutes | See below |
| Home Exercise Program | | | |
| 1–2 | Lower Extremity Strengthening | Seated lower extremity active range of motion to tolerance | See below |
| 3–13 | Lower Extremity Strengthening | Sit-to-stands with assistance of upper extremities 3 sets of 10 repetitions 2–3 times per day | See below |
| Exercise | | | |
| 1 | Lower Extremity Strengthening | Seated marching 3 sets X 10 repetitions with maximum verbal cueing Long arc quads: 3 sets X 10 repetitions with maximum verbal cueing | Patient able to perform lower extremity active range of motion with maximum verbal cueing. He requires maximum assistance X2 to ambulate with a rolling walker X20 feet |
| 2–8 | Gait Training Lower Extremity Strengthening | Ambulation with rolling walker X15 minutes Seated marching 3 sets X 10 repetitions Long arc quads: 3 sets X 10 repetitions Sit-to-stand at parallel bars with moderate-maximum assistance X3 minutes Upper/lower extremity cycling X10 minutes | Patient able to perform seated therapeutic exercise but requires moderate-maximum assistance to sit-to-stand and ambulate 10 steps in parallel bars. |
| 9 | Gait Training Lower Extremity Strengthening | Ambulation with parallel bars with moderate-maximum assistance X10 minutes Sit-to-stand at parallel bars with bar assistance X 10 repetitions Sit-to-stand at parallel bars with minimum-moderate assistance X 10 minutes | Patient able to perform seated therapeutic exercise but requires minimum-moderate assistance to sit-to-stand and ambulate 10 steps in parallel bars. |
| 10–11 | Gait Training Lower Extremity Strengthening | Ambulation with parallel bars with minimum-moderate assistance X10 minutes Sit-to-stand at parallel bars with contact-guard-minimum assistance X 10 repetitions Resisted knee flexion/extension from a seated position X3 minutes Upper/lower extremity cycling X10 minutes | Patient able to perform seated therapeutic exercise but requires contact-guard-minimum assistance to sit-to-stand and ambulate 10 steps in parallel bars. |
| 12–13 | Gait Training Lower Extremity Strengthening | Ambulation with parallel bars with contact-guard-minimum assistance X10 minutes Sit-to-stand independent X3 minutes Resisted knee flexion/extension from a seated position X3 minutes Upper/lower extremity cycling X10 minutes Ambulation over even/uneven surfaces with minimum verbal cueing for posture X5 minutes Ambulation with perturbations X5 minutes Ambulation on balance beam and airex X5 minutes | Patient able to perform seated therapeutic exercise and independently sit-to-stand and ambulate 10 steps in parallel bars. |

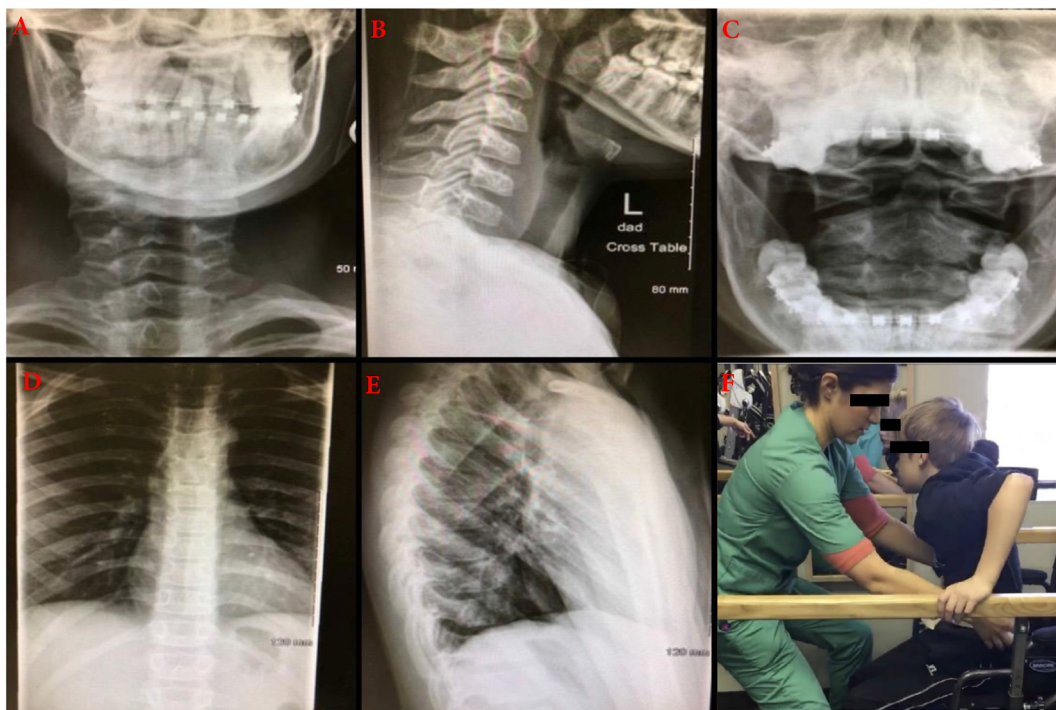


Fig. 1. A-E. Radiographic images taken of the patient's spine taken <2 Hours after the traumatic injury. F. Patient beginning physical therapy treatment. Note: the patient's family consented to all images included in this case report.

muscle strain in the cervical, thoracic, and lumbar spine. While paraspinal pain and muscle strain were clearly associated with the patient's condition, loss of strength, sensation, balance, and overall function suggested that the condition may be much more complicated. More specifically, the patient's mechanism of injury and symptoms suggested central nervous system involvement. In the absence of central nervous system involvement, the secondary goal was to find a possible musculoskeletal structure that could be propagating the patient's pain while disrupting the neural outflow from the central nervous system. The final goal of the evaluation was to confirm that the patient was safe to treat.

4. Examination

A number of tests were performed during the initial evaluation in order to determine central nervous system involvement. In addition to cranial nerve testing, Lhermitte's sign and Hoffman's signs were checked. Lhermitte's sign is 97% specific and 3–17% sensitive (Khare and Seth, 2015), while Hoffman's sign is 33.3% specific and 61.9% sensitive for non-specific compressive myelopathy (Saha et al., 2017). However, all cranial nerves were normal, and the patient did not have a positive Lhermitte or Hoffman's sign. Possible vascular pathology was also ruled out, as cranial nerve and positional testing were negative. Moreover, the patient's blood pressure was normal. While the patient did experience a dangerous method of injury, all other aspects of the Canadian C-spine rules were also negative. According to Stiell et al., the Canadian C-spine rules have a sensitivity of 100% (Stiell et al., 2001). Given the patient's unremarkable CT and MRI images of the C-spine, fractures were considered unlikely. The tectorial membrane and Sharp-Purser test were also performed in an effort to provoke and alleviate symptoms, respectively, associated with craniocervical instability (Hutting et al., 2013). Collectively, these tests are sensitive and specific for identifying patients with upper cervical spine instability (Hutting et al., 2013). Both special tests were negative.

The patient and his mother presented to physical therapy in a wheelchair with a diagnosis of cervical muscle strain along with cervical, thoracic, and lumbar pain. The patient was unable to utilize core or lower extremity muscles to ambulate, transfer, or sit with proper posture without pain. While the patient was able to move his toes in response to verbal and visual cueing, he was unable to move other muscles in the lower extremities or maintain unsupported sitting. A lower quarter scan revealed 1+/5 strength of the core and bilateral lower extremity muscles, which were primarily limited by pain. The patient also demonstrated loss of sensation to light touch over the dermatomes in both legs distal to mid-thigh. However, reflexes were 2+, bilaterally. While the patient could utilize his upper extremities, he was dependent for all transfers. The patient scored a 9/80 on the Lower Extremity Function Scale (LEFS) during initial evaluation.

Lateral glide testing was used to assess the facet joints in the cervical spine. Segmental hypomobility, paraspinal muscle hypertonicity, and general sensitivity were noted with lateral glide testing in the cervical spine (Jull et al., 1997). The patient further reported significant discomfort during Kemp's Test (Stuber et al., 2014), lumbar compression, and posterior to anterior glides over the thoracic and lumbar facet joints and spinous processes, further suggesting facet joint involvement (Rey-Eiriz et al., 2010). Although the patient reported discomfort during the cervical axial compression and Spurling's Test (Tong et al., 2002), he did not report increased radicular symptoms into the upper extremities. In general, the patient's cervical, thoracic, and lumbar paraspinal muscles seemed to be in a continuous state of spasm. They were sensitive to palpation with numerous palpable trigger points throughout.

5. Clinical findings

Based on the findings of the initial examination, the patient did not have a central nervous system lesion. However, pain, spasming,

and inflammation of the paraspinal muscles in the cervical, thoracic, and lumbar spine possibly disrupted the neural outflow from the periphery, causing significant weakness, loss of sensation, and decreased function (Korr, 1978; Pickar and Bolton, 2012). As such, the goal of physical therapy was to target the paraspinal muscles and facet joints so as to decrease the pain and inflammation, thereby improving the neural outflow to the core and lower extremities. Neither diagnostic images nor special testing revealed any precautions or contraindications to physical therapy, to include the use of SMT. The findings of the physical therapy evaluation were discussed with the patient, the patient's family, and the referring physician. Collectively, it was determined that moist heat with IFC, myofascial release (i.e. instrument-assisted soft tissue mobilization), exercise, gait training, and SMT would be included in the patient's plan of care.

6. Intervention

The patient received a total of 13 physical therapy treatment sessions over 5-weeks with at least one rest day between treatments. The patient was able to tolerate 1–2 weekly treatment sessions for the first 2-weeks followed by 2–3 weekly treatment sessions thereafter. Interventions included moist heat with IFC, myofascial release (i.e. instrument-assisted soft tissue mobilization), therapeutic exercise, gait training, and SMT. Consistent with previous investigations, spinal manipulation included the following techniques: cervical (C2–C7) rotatory HVLAT (cradle hold) (Dunning et al., 2020), cervicothoracic junction (C7-T3) lateral flexion HVLAT in prone (Dunning et al., 2017), mid-thoracic (T4-T9) A-P extension HVLAT in supine (Joo et al., 2020; Joshi et al., 2020), and lumbosacral junction (L5-S1) HVLAT in lateral recumbent with extension/rotation and sacral forearm pull (Mourad et al., 2019). With the exception of the mid-thoracic (T2-T9) P-A extension HVLAT in prone, all manipulation techniques were performed, bilaterally. All manipulation techniques were performed once during each of the 13 physical therapy treatment sessions. The goal of the manipulation techniques was to produce audible cavitations, which is generally considered an indicator of successful technique delivery among physical therapists, chiropractors, and osteopaths (Dunning et al., 2016; Evans and Lucas, 2010; Herzog et al., 1993; Reggars, 1996; Ross et al., 2004). Please see Table 2 for a detailed outline of the manual therapy techniques, modalities, and exercises given to this patient during 13 physical therapy treatment sessions.

7. Outcome

After evaluation and first treatment session, which included SMT, the patient was able to lift his legs into hip flexion and knee extension from a seated position with maximum verbal encouragement and cueing. The patient had 2+ / 5 core and bilateral lower extremity strength per manual muscle testing and was primarily limited by pain. He was also able to stand with maximum assistance of two people and use a rolling walker to take several steps. By treatment 12 and 13, the patient was able to ambulate independently with a normal gait pattern. Moreover, the patient returned to a previous level of function, including full return to sports. Following multimodal physical therapy, to include spinal manipulation, the patient scored an 80/80 on the LEFS. Please see Fig. 2 for images depicting the patient's progression across physical therapy treatments 1, 2, 3, and 12 (Note: The patient's level of function at treatment 12 was equal to that of treatment 13). Movies documenting this patient's progress are available online as supplementary files. At 6-months follow-up, the patient continued to participate in competitive sports with no functional limitations. Now 3.5 years after physical therapy treatment for symptoms

consistent with a SCIWORA, the patient reports no pain or limitations of any kind. Fig. 3 depicts patient playing competitive football 3.5 years posttraumatic injury.

8. Discussion

The results of this case report suggest that a combination of moist heat with IFC, myofascial release, exercise, gait training, and SMT of the cervical, thoracic, and lumbosacral regions, may be useful for patients with symptoms consistent with a SCIWORA. After 13 treatments, the 11-year-old wrestler achieved full recovery with resolution of pain, function, muscle strength, and balance. At 6-months follow-up, the patient demonstrated full return to competitive sports with no functional limitations, an outcome which persisted >3.5 years. While this single case cannot and should not represent an entire population of patients and no firm cause and effect can be established, it is perhaps worth noting that SMT was the component of the treatment that consistently led to the most dramatic improvements in pain and function, as evidenced by the patient's ability to ambulate and complete transitional movements independently. As mentioned earlier, mechanical, biochemical, and neurophysiologic response to SMT may help account for the aforementioned clinical improvements.

Although a topic of continued debate, a number of studies on cadavers (Gal et al., 1997) and live patients (Childs et al., 2004; Timgren and Soynila, 2006) have demonstrated a positional change of the arthokinematic structures of the zygoapophyseal joint pre to post manipulation, which could help alter segmental biomechanics by releasing trapped meniscoids, breaking adhesions, and improving distortion of intervertebral discs (Lewit, 1991; Pickar and Bolton, 2012). According to Triano et al., the new positional equilibrium could reduce mechanical stress and strain on both soft tissue and bone (Triano, 2001). The new position may relieve compression from the neural tissue in the intervertebral foramen, improve action potential frequency, increase axoplasmic transport, and reduce factors associated with inflammation (Korr, 1978; Pickar and Bolton, 2012). Song et al. reported significantly less hyperexcitability and inflammation of dorsal root ganglia neurons in an animal model of intervertebral foramen inflammation pre to post activator-assisted SMT (Song et al., 2006). In addition, the improper position of facet joints could activate nociceptors in the joint and paraspinal muscle spindles that are associated with the joint, leading to a cycle of gamma motor neuron gain and subsequent muscle spindle hypersensitivity (Clark et al., 2011). Excessive spinal stretch-reflex and alpha motor neuron activity, a phenomenon more formally referred to as the pain-spasm-pain cycle (van Dieen et al., 2003). The resulting paraspinal muscle hypertonicity could also compress neural tissue in the vicinity of the intervertebral foramen, causing radicular symptoms such as muscle weakness, loss of sensation, imbalance, and pain. Notably, the patient in the present study reported significant paraspinal muscle spasms and pain in the cervical, thoracic, and lumbar spine, which progressed to significant lower extremity muscle weakness, loss of sensation, and imbalance soon thereafter.

While muscle spindle discharge seems to increase during the course of high-velocity, low amplitude thrust procedures (Cao et al., 2013; Pickar and Kang, 2006; Pickar and Wheeler, 2001), a number of studies have reported an attenuation of the stretch-reflex and a significant decrease in the sensitivity of muscle spindles post-manipulation (Clark et al., 2011; Dishman and Bulbulian, 2000; Reed et al., 2017). Interestingly, muscle spindle desensitization was only achieved in the presence of an audible cavitation, which may be required to gap the joint and break fixations in order to restore the proper motion of the vertebral segment (Clark et al., 2011).

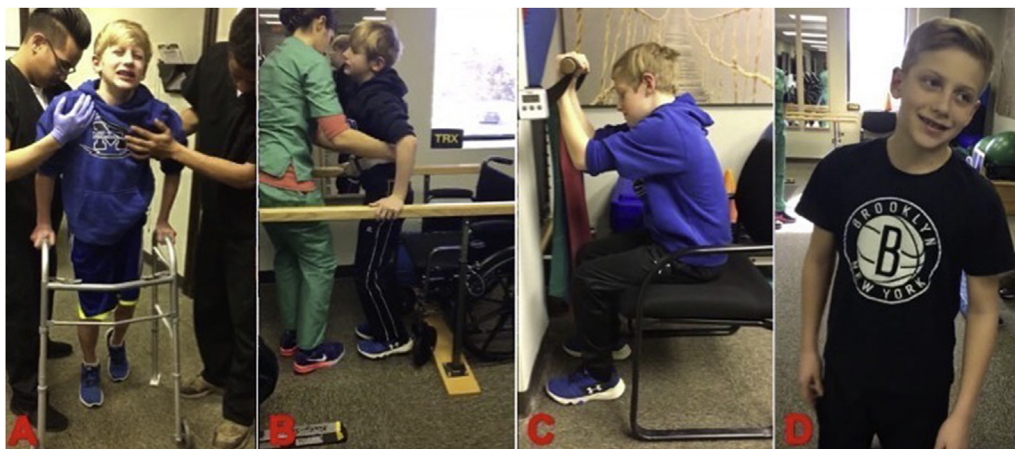

Fig. 2. Images depicting patient's progress across physical therapy treatments 1, 2, 3, and 12. Movies documenting the patient progress are available online as supplementary files. Note: the patient's family consented to all images and movies included in this case report.



Fig. 3. Patient playing competitive football 3.5 years after traumatic injury with symptoms consistent with SCIWORA. Note: the patient's family consented to all images included in this case report.

Other investigators have also proposed that SMT activates joint mechanoreceptors, spinal ligaments, intervertebral discs, cutaneous receptors, golgi tendon organs, and muscles spindles, which collectively work to inhibit alpha motor neuron excitability so as to correct muscle hypertonicity (Colloca et al., 2004; Pickar and Kang, 2006; Symons et al., 2000). A number of studies have specifically measured decreased paraspinal activity post SMT during movement (Bicalho et al., 2010; Tunnell, 2009) and at rest (DeVocht et al., 2005; Lehman et al., 2001; Orakifar et al., 2012). Dunning and Rushton further reported a significant decrease in the tone of the bilateral biceps brachii, a muscle segmentally and neuroanatomically associated with, but not attached to the spine, following a single manipulation targeting the right C5–C6 compared to control (Dunning and Rushton, 2009).

SMT has also been shown to have a significant effect on pain perception (Pickar, 2002; Vigotsky and Bruhns, 2015; Wright, 1995). Patients provoked with pain secondary to pressure, electricity, stretching, dermal irritation, and spontaneous stimuli all report improved tolerance following SMT (Millan et al., 2012). The literature reports improvements in local and regional pain pressure threshold from 4.8% to 44.6% (Hannam and McMillan, 1994). SMT is widely considered to inhibit pain, at least in part, via the Gait Control Theory of pain (Vigotsky and Bruhns, 2015). According to Melzack, substantia gelatinosa interneurons are stimulated by low

threshold Ab fibers, which inhibit neurons at the level of the dorsal horn (Melzack and Wall, 1965). While Vernon et al. measured a significant increase in plasma B-endorphin concentration following manipulation of the upper cervical spine vs. control (Vernon et al., 1986), subsequent investigations on SMT have published contradicting results (Christian et al., 1988). Moreover, Skyba et al. found that blocking receptors associated with serotonin and norepinephrine in the spinal cord attenuated the effects of knee joint manipulation, whereas blocking opioid channels with naloxone had no effect on analgesia (Skyba et al., 2003). As such, the initial hypoalgesic effects of SMT are thought to be propagated via descending pain inhibition via the periaqueductal grey (Wright, 1995). In short, the projections from the dorsal periaqueductal grey utilize norepinephrine to inhibit substance P evoked by painful mechanical stimuli, whereas the ventral periaqueductal grey uses serotonin to inhibit noxious thermal stimulation (Kuraishi, 1990; Wright, 1995).

According to Boal and Gillette, back trauma stimulates high-frequency firing of small, nociceptive type-C afferents, which drives spinal changes associated with hyperalgesia and referred pain via long-term potentiation (Boal and Gillette, 2004). Given that plastic changes begin to occur during the initial response to injury (Coderre et al., 1993), the patient in the present study was likely dealing with central and peripheral-mediated pain. However, SMT has been shown to stimulate low frequency, large, nociceptive type-Ad afferents, which have the ability to reverse central mediated changes associated with pain via long term depression (Boal and Gillette, 2004; Sandkuhler et al., 1997). Like the initial pain stimulus, Ad stimulation via SMT begins working from seconds to minutes following treatment and has been shown to last for hours (Boal and Gillette, 2004), which is consistent with the time course to change pain sensitivity in the low back following SMT.

Consistent with the patient in the present study, a number of investigations in the literature have demonstrated improvements in paraspinal (Cleland et al., 2004; Dunning et al., 2012; Keller and Colloca, 2000) and pelvic floor (de Almeida et al., 2010) muscle strength following spinal and sacroiliac manipulation, respectively. After performing SMT at lumbar vertebral levels that specifically innervated weak muscle groups, Chilibeck et al. also reported significant improvements in hip and knee flexor strength compared to placebo SMT (Chilibeck et al., 2011). The simplest explanation for improvements in muscle strength pre to post SMT may be a reduction of pain inhibition (Suter et al., 1999). However, there also seems to be an association between muscle strength post-

manipulation and H-reflexes and/or V-waves (Christiansen et al., 2018; Haavik et al., 2016; Niazi et al., 2015). While H reflexes are associated with increased motor neuron excitability and increased resistance to fatigue post strength (Aagaard et al., 2002) and endurance training, V-wave correspond with increased motor neuron excitability and maximal voluntary contraction secondary to increased descending neural drive (Aagaard et al., 2002; Haavik et al., 2016). While some researchers have associated increases in H-reflexes with improvements in muscle strength following SMT (Niazi et al., 2015), recent investigations have not reported any change in H-reflex pre to post SMT (Christiansen et al., 2018; Haavik et al., 2016). Rather, the increase in muscle strength seems to correlate best with the corticospinal excitability represented by V-waves (Christiansen et al., 2018; Haavik et al., 2016).

9. Limitations

This is a single case report; therefore, no firm cause and effect relationships can be established. While the patient subjectively felt that they benefited most from the SMT, there is no way to truly determine the importance of moist heat with IFC, myofascial release, exercise to this patient's recovery. In reality, a multi-prong approach was appropriate. Also, while the patient had a mechanism of injury and symptoms consistent with a SCIWORA, the patient was not formally diagnosed with this condition. We cannot rule out the possibility of a transient tetraplegia or that the patient spontaneously recovered as opposed to benefiting directly from the physical therapy treatment. Importantly, patients with a SCIWORA or any traumatic injury involving the spine should be carefully evaluated prior to treatment, particularly with SMT. In this case, images of the patient's spine were taken, and the patient was carefully screened for red flags. A decision to incorporate SMT into the patient's plan of care was made only after consent of the patient, the patient's family, and a formal risk analysis was done with the referring physician.

10. Conclusion

The results of the present case report suggest that SMT may be an effective strategy for pediatric patients that present with signs and symptoms consistent with SCIWORA, particularly when packaged as part of a multi-modal treatment strategy. More research is warranted in order to provide adequate evidence to support SMT in the pediatric population.

Funding

None.

CRedit authorship contribution statement

Raymond Butts: Writing original draft, Data curation, Formal analysis, writing review and editing, Conceptualization, Investigation, Dr. **Owen Legaspi:** Writing review and editing, Supervision, providing patient information and treatment method. Dr. **Adriana Nocera-Mekel:** Formal analysis, writing original draft, Conceptualization, providing patient information and treatment method, Investigation, Dr. **James Dunning:** Writing review and editing, Resources, Supervision.

Declaration of competing interest

Dr Dunning is the President of the American Academy of Manipulative Therapy (AAMT) and the Director of the AAMT Fellowship in Orthopaedic Manual Physical Therapy. The AAMT

provides postgraduate training programs in spinal manipulation, spinal mobilization, dry needling, extremity manipulation, extremity mobilization, instrument-assisted soft tissue mobilization, therapeutic exercise, and differential diagnosis to licensed physical therapists, osteopaths, and medical doctors. Drs Dunning and Butts receive a fee from the AAMT for teaching weekend continuing education courses in the aforementioned subject matters. The other authors certify that they have no affiliations with or financial involvement in any organization or entity with a direct financial interest in the subject matter or materials discussed in the article. None of the authors received any funding for this study.

Acknowledgements

None.

Appendix A. Supplementary data

Supplementary data to this article can be found online at <https://doi.org/10.1016/j.jbmt.2021.01.008>.

References

- Aagaard, P., Simonsen, E.B., Andersen, J.L., Magnusson, P., Dyhre-Poulsen, P., 2002. 2002 Neural adaptation to resistance training: changes in evoked V-wave and H-reflex responses. *J. Appl. Physiol.* 92, 2309–2318.
- Abdulla, S.Y., Southerst, D., Cote, P., Shearer, H.M., Sutton, D., Randhawa, K., Varatharajan, S., Wong, J.J., Yu, H., Marchand, A.A., Chrobak, K., Woitzik, E., Shergill, Y., Ferguson, B., Stupar, M., Nordin, M., Jacobs, C., Mior, S., Carroll, L.J., van der Velde, G., Taylor-Vaisey, A., 2015. Is exercise effective for the management of subacromial impingement syndrome and other soft tissue injuries of the shoulder? A systematic review by the Ontario Protocol for Traffic Injury Management (OPTIMA) Collaboration. *Man. Ther.* 20, 646–656.
- Alcantara, J., Davis, J., 2011. The chiropractic care of children with "growing pains": a case series and systematic review of the literature. *Compl. Ther. Clin. Pract.* 17, 28–32.
- Alshorman, J., Wang, Y., Zhu, F., Zeng, L., Chen, K., Yao, S., Jing, X., Guo, X., 2020. Clinical diagnosis and treatment of spinal cord injury without evidence of abnormality in children: a review. *Int. Surg. J* 7, 3847–3855.
- Atesok, K., Tanaka, N., O'Brien, A., Robinson, Y., Pang, D., Deinlein, D., Manoharan, S.R., Pittman, J., Theiss, S., 2018. 2018 posttraumatic spinal cord injury without radiographic abnormality. *Adv Orthop* 7060654.
- Austin, N., DiFrancesco, L.M., Herzog, W., 2010. Microstructural damage in arterial tissue exposed to repeated tensile strains. *J. Manip. Physiol. Ther.* 33, 14–19.
- Bicalho, E., Setti, J.A., Macagnan, J., Cano, J.L., Manfira, E.F., 2010. Immediate effects of a high-velocity spine manipulation in paraspinal muscles activity of nonspecific chronic low-back pain subjects. *Man. Ther.* 15, 469–475.
- Boal, R.W., Gillette, R.G., 2004. Central neuronal plasticity, low back pain and spinal manipulative therapy. *J. Manip. Physiol. Ther.* 27, 314–326.
- Bolin, D.J., 2010. The application of osteopathic treatments to pediatric sports injuries. *Pediatr. Clin.* 57, 775–794.
- Bonfanti, L., Donelli, V., Lunian, M., Davide, C., Francesca, C., Gianfranco, C., 2018. Adult spinal cord injury without radiographic abnormality (SCIWORA). Two case reports and a narrative review. *Acta Biomed.* 89, 593–598.
- Bronfort, G., Haas, M., Evans, R.L., Bouter, L.M., 2004. Efficacy of spinal manipulation and mobilization for low back pain and neck pain: a systematic review and best evidence synthesis. *Spine J.* 4, 335–356.
- Burke, D.C., 1974. Traumatic spinal paralysis in children. *Paraplegia* 11, 268–276.
- Buzzatti, L., Provyn, S., Van Roy, P., Cattrysse, E., 2015. Atlanto-axial facet displacement during rotational high-velocity low-amplitude thrust: an in vitro 3D kinematic analysis. *Man. Ther.* 20, 783–789.
- Cao, D.Y., Reed, W.R., Long, C.R., Kawchuk, G.N., Pickar, J.G., 2013. Effects of thrust amplitude and duration of high-velocity, low-amplitude spinal manipulation on lumbar muscle spindle responses to vertebral position and movement. *J. Manip. Physiol. Ther.* 36, 68–77.
- Childs, J.D., Piva, S.R., Erhard, R.E., 2004. Immediate improvements in side-to-side weight bearing and iliac crest symmetry after manipulation in patients with low back pain. *J. Manip. Physiol. Ther.* 27, 306–313.
- Chilibeck, P.D., Cornish, S.M., Schulte, A., Jantz, N., Magnus, C.R., Schwanbeck, S., Juurlink, B.H., 2011. The effect of spinal manipulation on imbalances in leg strength. *J. Can. Chiropr. Assoc.* 55, 183–192.
- Christian, G.F., Stanton, G.J., Sissons, D., How, H.Y., Jamison, J., Alder, B., Fullerton, M., Funder, J.W., 1988. Immunoreactive ACTH, beta-endorphin, and cortisol levels in plasma following spinal manipulative therapy. *Spine* 13, 1411–1417.
- Christiansen, T.L., Niazi, I.K., Holt, K., Nedergaard, R.W., Duehr, J., Allen, K., Marshall, P., Turker, K.S., Hartvigsen, J., Haavik, H., 2018. The effects of a single session of spinal manipulation on strength and cortical drive in athletes. *Eur. J. Appl. Physiol.* 118, 737–749.

- Cirak, B., Ziegfeld, S., Knight, V.M., Chang, D., Avellino, A.M., Paidas, C.N., 2004. Spinal injuries in children. *J. Pediatr. Surg.* 39, 607–612.
- Clark, B.C., Goss Jr., D.A., Walkowski, S., Hoffman, R.L., Ross, A., Thomas, J.S., 2011. Neurophysiologic effects of spinal manipulation in patients with chronic low back pain. *BMC Musculoskel. Disord.* 12, 170.
- Cleland, J., Selleck, B., Stowell, T., Browne, L., Alberini, S., St Cyr, H., Caron, T., 2004. Short-term effects of thoracic manipulation on lower trapezius muscle strength. *J. Man. Manip. Ther.* 12, 82.
- Coderre, T.J., Katz, J., Vaccarino, A.L., Melzack, R., 1993. Contribution of central neuroplasticity to pathological pain: review of clinical and experimental evidence. *Pain* 52, 259–285.
- Colloca, C.J., Keller, T.S., Gunzburg, R., 2004. Biomechanical and neurophysiological responses to spinal manipulation in patients with lumbar radiculopathy. *J. Manip. Physiol. Ther.* 27, 1–15.
- de Almeida, B.S., Sabatino, J.H., Giraldo, P.C., 2010. Effects of high-velocity, low-amplitude spinal manipulation on strength and the basal tonus of female pelvic floor muscles. *J. Manip. Physiol. Ther.* 33, 109–116.
- DeVocht, J.W., Pickar, J.G., Wilder, D.G., 2005. Spinal manipulation alters electromyographic activity of paraspinal muscles: a descriptive study. *J. Manip. Physiol. Ther.* 28, 465–471.
- Dhal, A., Roy, K., Ghosh, S., 2006. A study on pediatric spinal injury: an IPGMR, Kolkata experience. *The Indian Journal of Neurotrauma* 3, 41–48.
- Dishman, J.D., Bulbulian, R., 2000. Spinal reflex attenuation associated with spinal manipulation. *Spine* 25, 2519–2524 discussion 2525.
- Dunning, J., Rushton A 2009 the effects of cervical high-velocity low-amplitude thrust manipulation on resting electromyographic activity of the biceps brachii muscle. *Man. Ther.* 14, 508–513.
- Dunning, J.R., Cleland, J.A., Waldrop, M.A., Arnot, C.F., Young, I.A., Turner, M., Sigurdsson, G., 2012. Upper cervical and upper thoracic thrust manipulation versus nonthrust mobilization in patients with mechanical neck pain: a multicenter randomized clinical trial. *J. Orthop. Sports Phys. Ther.* 42, 5–18.
- Dunning, J.R., Butts, R., Mourad, F., Young, I., Fernandez-de-Las Penas, C., Hagins, M., Stanislawski, T., Donley, J., Buck, D., Hooks, T.R., Cleland, J.A., 2016. Upper cervical and upper thoracic manipulation versus mobilization and exercise in patients with cervicogenic headache: a multi-center randomized clinical trial. *BMC Musculoskel. Disord.* 17, 64.
- Dunning, J., Mourad, F., Zingoni, A., Iorio, R., Perreault, T., Zacharko, N., de Las Penas, C.F., Butts, R., Cleland, J.A., 2017. Cavitation sounds during cervicothoracic spinal manipulation. *Int J Sports Phys Ther* 12, 642–654.
- Dunning, J., Butts, R., Fernandez-de-Las-Penas, C., Walsh, S., Goult, C., Gillett, B., Arias-Buria, J.L., Garcia, J., Young, I.A., 2020. Spinal manipulation and electrical dry needling in patients with subacromial pain syndrome: a multicenter randomized clinical trial. *J. Orthop. Sports Phys. Ther.* 1–46.
- Erhardt, J.W., Windsor, B.A., Kerry, R., Hoekstra, C., Powell, D.W., Porter-Hoke, A., Taylor, A., 2015. The immediate effect of atlanto-axial high velocity thrust techniques on blood flow in the vertebral artery: a randomized controlled trial. *Man. Ther.* 20, 614–622.
- Evans, D.W., Lucas, N., 2010. What is 'manipulation'? A reappraisal. *Man. Ther.* 15, 286–291.
- Gal, J., Herzog, W., Kawchuk, G., Conway, P.J., Zhang, Y.T., 1997. Movements of vertebrae during manipulative thrusts to unembalmed human cadavers. *J. Manip. Physiol. Ther.* 20, 30–40.
- Garcia, J.D., Arnold, S., Tetley, K., Voight, K., Frank, R.A., 2016. Mobilization and manipulation of the cervical spine in patients with cervicogenic headache: any scientific evidence? *Front. Neurol.* 7, 40.
- Grieve, G., 1981. *Common Vertebral Joint Problems*, London.
- Haavik, H., Murphy, B., 2012. The role of spinal manipulation in addressing disordered sensorimotor integration and altered motor control. *J. Electromyogr. Kinesiol.* 22, 768–776.
- Haavik, H., Niazi, I.K., Jochumsen, M., Sherwin, D., Flavel, S., Turker, K.S., 2016. Impact of spinal manipulation on cortical drive to upper and lower limb muscles. *Brain Sci.* 7.
- Hannam, A.G., McMillan, A.S., 1994. Internal organization in the human jaw muscles. *Crit. Rev. Oral Biol. Med.* 5, 55–89.
- Herzog, W., Zhang, Y.T., Conway, P.J., Kawchuk, G.N., 1993. Cavitation sounds during spinal manipulative treatments. *J. Manip. Physiol. Ther.* 16, 523–526.
- Heydemann, J., Kaufman, B., Shah, S., 2020. Spinal cord injury without radiographic abnormalities (SCIWORA). In: *Lobst, C., Frick, S. (Eds.), Pediatric Orthopedic Trauma Case Atlas*. Springer, Cham.
- Hurwitz, E.L., Carragee, E.J., van der Velde, G., Carroll, L.J., Nordin, M., Guzman, J., Peloso, P.M., Holm, L.W., Cote, P., Hogg-Johnson, S., Cassidy, J.D., Haldeman, S., 2009. Treatment of neck pain: noninvasive interventions: results of the bone and joint decade 2000–2010 task force on neck pain and its associated disorders. *J. Manip. Physiol. Ther.* 32, S141–S175.
- Hutting, N., Scholten-Peeters, G.G., Vijverman, V., Keesenberg, M.D., Verhagen, A.P., 2013. Diagnostic accuracy of upper cervical spine instability tests: a systematic review. *Phys. Ther.* 93, 1686–1695.
- Jaros, D.A., 1999. Pediatric spinal cord injuries: a case presentation. *Crit. Care Nurs.* 22, 8–13.
- Joo, S., Kim, J., Lee, Y., Song, C., 2020. The biomechanical analysis of magnitude and direction of force by different techniques of thoracic spinal manipulation. *BioMed Res. Int.* 2020, 8928071.
- Joshi S, Balthillaya G, Neelapala YVR 2020 Immediate effects of cervicothoracic junction mobilization versus thoracic manipulation on the range of motion and pain in mechanical neck pain with cervicothoracic junction dysfunction: a pilot randomized controlled trial. *Chiropr. Man. Ther.* 28, 38.
- Jull, G., Zito, G., Trott, P., Potter, H., Shirley, D., 1997. Inter-examiner reliability to detect painful upper cervical joint dysfunction. *Aust. J. Physiother.* 43, 125–129.
- Kachmar, O., Voloshyn, T., Hordiyevych, M., 2016. Changes in muscle spasticity in patients with cerebral palsy after spinal manipulation: case series. *J. Chiropr. Med* 15, 299–304.
- Keller TS, Colloca CJ 2000 Mechanical force spinal manipulation increases trunk muscle strength assessed by electromyography: a comparative clinical trial. *J. Manip. Physiol. Ther.* 23, 585–595.
- Khare, S., Seth, D., 2015. Lhermitte's sign: the current status. *Ann. Indian Acad. Neurol.* 18, 154–156.
- Korr, I., 1978. *The Neurobiologic Mechanisms in Manipulative Therapy*. Plenum Press, New York.
- Kriss, V.M., Kriss, T.C., 1996. SCIWORA (spinal cord injury without radiographic abnormality) in infants and children. *Clin. Pediatr.* 35, 119–124.
- Kuraishi, Y., 1990. Neuropeptide-mediated transmission of nociceptive information and its regulation. Novel mechanisms of analgesics. *Yakugaku Zasshi* 110, 711–726.
- Lehman, G.J., Vernon, H., McGill, S.M., 2001. Effects of a mechanical pain stimulus on erector spinae activity before and after a spinal manipulation in patients with back pain: a preliminary investigation. *J. Manip. Physiol. Ther.* 24, 402–406.
- Leininger, B.D., Evans, R., Bronfort, G., 2014. Exploring patient satisfaction: a secondary analysis of a randomized clinical trial of spinal manipulation, home exercise, and medication for acute and subacute neck pain. *J. Manip. Physiol. Ther.* 37, 593–601.
- Lewit, K., 1991. *Manipulative Therapy in the Rehabilitation of the Locomotor System*. Butterworth-Heinemann, Oxford.
- Melzack R, Wall PD 1965 Pain mechanisms: a new theory. *Science* 150, 971–979.
- Michaleff, Z.A., Lin, C.W., Maher, C.G., van Tulder, M.W., 2012. Spinal manipulation epidemiology: systematic review of cost effectiveness studies. *J. Electromyogr. Kinesiol.* 22, 655–662.
- Millan, M., Leboeuf-Yde, C., Budgell, B., Amorim, M.A., 2012. The effect of spinal manipulative therapy on experimentally induced pain: a systematic literature review. *Chiropr. Man. Ther.* 20, 26.
- Mourad, F., Dunning, J., Zingoni, A., Iorio, R., Butts, R., Zacharko, N., Fernandez-de-Las-Penas, C., 2019. Unilateral and multiple cavitation sounds during lumbosacral spinal manipulation. *J. Manip. Physiol. Ther.* 42, 12–22.
- Murphy, D.R., 2010. Current understanding of the relationship between cervical manipulation and stroke: what does it mean for the chiropractic profession? *Chiropr. Osteopat* 18, 22.
- Niazi, I.K., Turker, K.S., Flavel, S., Kinget, M., Duehr, J., Haavik, H., 2015. Changes in H-reflex and V-waves following spinal manipulation. *Exp. Brain Res.* 233, 1165–1173.
- Oliveira-Campelo, N.M., Rubens-Rebelatto, J., Marti, N.V.F.J., Albuquerque-Sendi, N.F., Fernandez-de-Las-Penas, C., 2010. The immediate effects of atlanto-occipital joint manipulation and suboccipital muscle inhibition technique on active mouth opening and pressure pain sensitivity over latent myofascial trigger points in the masticatory muscles. *J. Orthop. Sports Phys. Ther.* 40, 310–317.
- Orakifar, N., Kamali, F., Pirouzi, S., Jamshidi, F., 2012. Sacroiliac joint manipulation attenuates alpha-motoneuron activity in healthy women: a quasi-experimental study. *Arch. Phys. Med. Rehabil.* 93, 56–61.
- Pang, D., Pollack, I.F., 1989. Spinal cord injury without radiographic abnormality in children—the SCIWORA syndrome. *J. Trauma* 29, 654–664.
- Pang, D., Wilberger Jr., J.E., 1982. Spinal cord injury without radiographic abnormalities in children. *J. Neurosurg.* 57, 114–129.
- Pickar, J.G., 2002. Neurophysiological effects of spinal manipulation. *Spine* 27, 357–371.
- Pickar, J.G., Bolton, P.S., 2012. Spinal manipulative therapy and somatosensory activation. *J. Electromyogr. Kinesiol.* 22, 785–794.
- Pickar, J.G., Kang, Y.M., 2006. Paraspinal muscle spindle responses to the duration of a spinal manipulation under force control. *J. Manip. Physiol. Ther.* 29, 22–31.
- Pickar, J.G., Wheeler, J.D., 2001. Response of muscle proprioceptors to spinal manipulative-like loads in the anesthetized cat. *J. Manip. Physiol. Ther.* 24, 2–11.
- Plaza-Manzano, G., Molina-Ortega, F., Lomas-Vega, R., Martinez-Amat, A., Achalandabaso, A., Hita-Contreras, F., 2014. Changes in biochemical markers of pain perception and stress response after spinal manipulation. *J. Orthop. Sports Phys. Ther.* 44, 231–239.
- Quesnele, J.J., Triano, J.J., Noseworthy, M.D., Wells, G.D., 2014. Changes in vertebral artery blood flow following various head positions and cervical spine manipulation. *J. Manip. Physiol. Ther.* 37, 22–31.
- Reed, W.R., Pickar, J.G., Sozio, R.S., Liebschner, M.A.K., Little, J.W., Gudavalli, M.R., 2017. Characteristics of paraspinal muscle spindle response to mechanically assisted spinal manipulation: a preliminary report. *J. Manip. Physiol. Ther.* 40, 371–380.
- Reggars, J.W., 1996. The manipulative crack. Frequency analysis. *Australas. Chiropr. Osteopathy* 5, 39–44.
- Rey-Eiriz, G., Albuquerque-Sendi, F., Barrera-Mellado, I., Martin-Vallejo, F., Fernandez-de-Las Penas, C., 2010. Validity of the posterior-anterior middle cervical spine gliding test for the examination of intervertebral joint hypomobility in mechanical neck pain. *J. Manipulative Physiol. Therapeut.* 33, 279–285.
- Roberts, J., Wolfe, T., 2009. Chiropractic care of a 6-year-old girl with neck pain; headaches; hand, leg, and foot pain; and other nonmusculoskeletal symptoms. *J. Chiropr. Med* 8, 131–136.
- Robinson, K., Jorgensen, S., Towbin, A., Towbin, R., 2015. *Applied Radiology*. Applied

- Radiology, pp. 26–28.
- Ross, J.K., Bereznick, D.E., McGill, S.M., 2004. Determining cavitation location during lumbar and thoracic spinal manipulation: is spinal manipulation accurate and specific? *Spine* 29, 1452–1457.
- Rubinstein, S.M., 2008. Adverse events following chiropractic care for subjects with neck or low-back pain: do the benefits outweigh the risks? *J. Manip. Physiol. Ther.* 31, 461–464.
- Saha, M., Uddin, K., Ahmed, M., Alam, S., Rahman, A., Chowdhury, D., Hossain, A., 2017. Determination of sensitivity and specificity of Hoffmann's sign in the diagnosis of patients with compressive cervical myelopathy. *Bangladesh Journal of Neurosurgery* 7.
- Sandkuhler J, Chen JG, Cheng G, Randic M 1997 Low-frequency stimulation of afferent Adelta-fibers induces long-term depression at primary afferent synapses with substantia gelatinosa neurons in the rat. *J. Neurosci.* 17, 6483–6491.
- Savva, C., Giakas, G., Efstathiou, M., 2014. The role of the descending inhibitory pain mechanism in musculoskeletal pain following high-velocity, low amplitude thrust manipulation: a review of the literature. *J. Back Musculoskelet. Rehabil.* 27, 377–382.
- Schellenberg, M., Islam, O., Pokrupa, R., 2011. Traumatic spinal cord injury without initial MRI abnormality: SCIWORA revisited. *Can. J. Neurol. Sci.* 38, 364–366.
- Shafir, Y., Kaufman, B.A., 1992. Quadriplegia after chiropractic manipulation in an infant with congenital torticollis caused by a spinal cord astrocytoma. *J. Pediatr.* 120, 266–269.
- Skyba, D.A., Radhakrishnan, R., Rohlwing, J.J., Wright, A., Sluka, K.A., 2003. Joint manipulation reduces hyperalgesia by activation of monoamine receptors but not opioid or GABA receptors in the spinal cord. *Pain* 106, 159–168.
- Song, X.J., Gan, Q., Cao, J.L., Wang, Z.B., Rupert, R.L., 2006. Spinal manipulation reduces pain and hyperalgesia after lumbar intervertebral foramen inflammation in the rat. *J. Manip. Physiol. Ther.* 29, 5–13.
- Spiegelblatt, L., 2002. Chiropractic care for children: controversies and issues. *Paediatr. Child Health* 7, 85–104.
- Stiell, I.G., Wells, G.A., Vandemheen, K.L., Clement, C.M., Lesiuk, H., De Maio, V.J., Laupacis, A., Schull, M., McKnight, R.D., Verbeek, R., Brison, R., Cass, D., Dreyer, J., Eisenhauer, M.A., Greenberg, G.H., MacPhail, I., Morrison, L., Reardon, M., Worthington, J., 2001. The Canadian C-spine rule for radiography in alert and stable trauma patients. *J. Am. Med. Assoc.* 286, 1841–1848.
- Stuber, K., Lerede, C., Kristmanson, K., Sajko, S., Bruno, P., 2014. The diagnostic accuracy of the Kemp's test: a systematic review. *J. Can. Chiropr. Assoc.* 58, 258–267.
- Suter, E., McMorland, G., Herzog, W., Bray, R., 1999. Decrease in quadriceps inhibition after sacroiliac joint manipulation in patients with anterior knee pain. *J. Manip. Physiol. Ther.* 22, 149–153.
- Symons, B.P., Herzog, W., Leonard, T., Nguyen, H., 2000. Reflex responses associated with activator treatment. *J. Manip. Physiol. Ther.* 23, 155–159.
- Symons, B.P., Leonard, T., Herzog, W., 2002. Internal forces sustained by the vertebral artery during spinal manipulative therapy. *J. Manip. Physiol. Ther.* 25, 504–510.
- Szwedowski D, Walecki J 2014 spinal cord injury without radiographic abnormality (SCIWORA) - clinical and radiological aspects. *Pol. J. Radiol.* 79, 461–464.
- Thomas, L.C., Rivett, D.A., Bateman, G., Stanwell, P., Levi, C.R., 2013. Effect of selected manual therapy interventions for mechanical neck pain on vertebral and internal carotid arterial blood flow and cerebral inflow. *Phys. Ther.* 93, 1563–1574.
- Tieppo Francio, V., Towery, C., Davani, S., Brown, T., 2017. Spinal manipulation and therapeutic exercises in treating post-surgical resurgent lumbar radiculopathy. *Oxf Med Case Reports* 2017 omx062.
- Timgren, J., Soinila, S., 2006. Reversible pelvic asymmetry: an overlooked syndrome manifesting as scoliosis, apparent leg-length difference, and neurologic symptoms. *J. Manip. Physiol. Ther.* 29, 561–565.
- Todd, A.J., Carroll, M.T., Robinson, A., Mitchell, E.K., 2015. Adverse events due to chiropractic and other manual therapies for infants and children: a review of the literature. *J. Manip. Physiol. Ther.* 38, 699–712.
- Tong, H.C., Haig, A.J., Yamakawa, K., 2002. The Spurling test and cervical radiculopathy. *Spine* 27, 156–159.
- Triano, J., 2001. *Clinical Biomechanics of Spinal Manipulation*. Churchill Livingstone, New York.
- Tunnell, J., 2009. Needle EMG response of lumbar multifidus to manipulation in the presence of clinical instability. *J. Man. Manip. Ther.* 17, E19–E24.
- UBT Team, 2004. United Kingdom back pain exercise and manipulation (UK BEAM) randomised trial: effectiveness of physical treatments for back pain in primary care. *BMJ* 329, 1377.
- van Dieen, J.H., Selen, L.P., Cholewicki, J., 2003. Trunk muscle activation in low-back pain patients, an analysis of the literature. *J. Electromyogr. Kinesiol.* 13, 333–351.
- Vernon, H.T., Dhami, M.S., Howley, T.P., Annett, R., 1986. Spinal manipulation and beta-endorphin: a controlled study of the effect of a spinal manipulation on plasma beta-endorphin levels in normal males. *J. Manip. Physiol. Ther.* 9, 115–123.
- Vigotsky, A.D., Bruhns, R.P., 2015. The role of descending modulation in manual therapy and its analgesic implications: a narrative review. *Pain Res Treat* 2015, 292805.
- Vindigni, D., Zark, L., Sundberg, T., Leach, M., Adams, J., Azari, M.F., 2019. Chiropractic treatment of older adults with neck pain with or without headache or dizziness: analysis of 288 Australian chiropractors' self-reported views. *Chiropr. Man. Ther.* 27, 65.
- Vining, R.D., Gosselin, D.M., Thurmond, J., Case, K., Bruch, F.R., 2017. Interdisciplinary rehabilitation for a patient with incomplete cervical spinal cord injury and multimorbidity: a case report. *Medicine (Baltim.)* 96, e7837.
- Vining, R.D., Salsbury, S.A., Cooley, W.C., Gosselin, D., Corber, L., Goertz, C.M., 2018. Patients receiving chiropractic care in a neurorehabilitation hospital: a descriptive study. *J. Multidiscip. Healthc.* 11, 223–231.
- Waimers, S., 2002. Pediatric chiropractic. *J. Paediatr. Child Health* 7, 114–115.
- Walston, Z., Yake, D., 2016. Lumbar thrust manipulation and exercise for the treatment of mechanical low back pain in adolescents: a case series. *J. Orthop. Sports Phys. Ther.* 46, 391–398.
- Wand, B.M., Heine, P.J., O'Connell, N.E., 2012. Should we abandon cervical spine manipulation for mechanical neck pain? *Yes. BMJ* 344, e3679.
- Wright, A., 1995. Hypoalgesia post-manipulative therapy: a review of a potential neurophysiological mechanism. *Man. Ther.* 1, 11–16.
- Wuest, S., Symons, B., Leonard, T., Herzog, W., 2010. Preliminary report: biomechanics of vertebral artery segments C1–C6 during cervical spinal manipulation. *J. Manip. Physiol. Ther.* 33, 273–278.
- Young, I.A., Pozzi, F., Dunning, J., Linkonis, R., Michener, L.A., 2019. Immediate and short-term effects of thoracic spine manipulation in patients with cervical radiculopathy: a randomized controlled trial. *J. Orthop. Sports Phys. Ther.* 49, 299–309.
- Zhao, P., Feng, T.Y., 1997. Protruded lumbar intervertebral nucleus pulposus in a 12-year-old girl who recovered after nonsurgical treatment: a follow-up case report. *J. Manip. Physiol. Ther.* 20, 551–556.